

A STUDY ON CLINICAL PROFILE OF ECTOPIC THYROID GLAND FROM A TERTIARY CARE HOSPITAL

K. Neelaveni¹, A. Datta Reddy², Rakesh Kumar Sahay³

¹Associate Professor, Department of Endocrinology, Osmania Medical College, Osmania General Hospital, Hyderabad.

²Senior Resident, Department of Endocrinology, Osmania Medical College, Osmania General Hospital, Hyderabad.

³Professor and HOD, Department of Endocrinology, Osmania Medical College, Osmania General Hospital, Hyderabad.

ABSTRACT

BACKGROUND

Ectopic thyroid tissue is a rare developmental abnormality due to aberrant embryogenesis of the thyroid gland during its descent from the floor of the primitive foregut to its final position in the neck.

Objective is to study the clinical characteristics of patients with ectopic thyroid gland.

MATERIALS AND METHODS

In this case series study, we retrospectively reviewed the medical records of 21 patients with ectopic thyroid gland attending the endocrinology clinic of tertiary care teaching hospital between August 2011 and August 2016. Clinical presentation, thyroid status, nuclear imaging and management outcomes were analysed.

RESULTS

Mean age of presentation was 13.62 years (Range 3-37 years). Fifteen patients were female and six were male (Ratio 5:2). Fourteen patients (66.67%) had lingual thyroid, whereas four patients (19.02%) had thyroid gland at suprahyoid and two patients (9.52%) had at subhyoid location. Only one patient had dual thyroid. Nineteen patients (90.48%) had thyroid deficiency (subclinical hypothyroidism in 38% or overt hypothyroidism in 52.38%) and only two (9.52%) were euthyroid. Seventeen patients (80.95%) were treated medically, only two (9.52%) patients underwent surgery. In twelve patients (57.14%) ectopic thyroid gland was detected incidentally, whereas six patients (28.57%) presented with neck swelling, two patients (9.52%) with dysphagia and one patient (4.76%) with dysphagia and respiratory difficulty.

CONCLUSION

Ectopic thyroid gland is rare, but important diagnosis to be considered especially in children with hypothyroidism. Clinical examination and nuclear imaging aid in correct diagnosis. Treatment should be individualised.

KEYWORDS

Ectopic, Eutopic Gland, Orthotopic Thyroid, Lingual Thyroid, Sublingual Thyroid, Subhyoid.

HOW TO CITE THIS ARTICLE: Neelaveni K, Reddy AD, Sahay RK. A study on clinical profile of ectopic thyroid gland from a tertiary care hospital. J. Evolution Med. Dent. Sci. 2016;5(82):6133-6136, DOI: 10.14260/jemds/2016/1385

INTRODUCTION

Ectopic Thyroid (ET) is a rare developmental abnormality, but one of the common form of thyroid dysgenesis. Ectopic thyroid refers to presence of functioning thyroid tissue in any location other than the normal pretracheal position. Mostly ectopic thyroid tissue is located in the midline along the line of descent, but occurrence in locations away from neck region, such as mediastinum and abdomen have been reported.^(1,2,3,4) The most frequent location is the base of the tongue, where presence of ET may cause difficulty in swallowing and respiratory difficulty. Reported prevalence of ectopic thyroid is between 1 per 100000-300000 persons, but the prevalence rises to 1 in 4000-8000 among patients with thyroid disease.⁽⁵⁾ Postmortem studies⁽⁶⁾ have reported that 7-10% of adults can have asymptomatic ectopic thyroid tissue located along the path of descent. To date approximately 550 cases of thyroid

ectopia have been reported in the literature. We describe the clinical presentation, location, thyroid functional status and management of patients with ectopic thyroid gland.

MATERIALS AND METHODS

We retrospectively analysed the medical records of patients diagnosed to have ectopic thyroid gland, who presented to the Endocrinology Clinic of a tertiary care teaching hospital between August 2011 and August 2016. Out of the total 24 patients only data of 21 patients analysed in the present study, as the data for the other three patients was incomplete. Clinical presentation, thyroid hormone profile, nuclear scan imaging of thyroid and the treatment modalities were analysed. Serum estimations of total T3, total T4 and thyrotropin (TSH) were done using chemiluminescence. Euthyroid status is defined as having TSH < 5 mIU/L with normal T4, subclinical hypothyroidism as having TSH > 5 mIU/L with normal T4 and overt hypothyroidism with TSH > 10 mIU/L and low T4. Nuclear imaging for thyroid was done using technetium Tc99m pertechnetate with gamma camera. Based on the clinical examination and nuclear imaging, location of the ectopic thyroid was classified as 1. Lingual thyroid-situated at the base of the tongue, 2. Suprahyoid-situated between base of the tongue and hyoid, 3. Subhyoid-below the hyoid but above the orthotopic position of the thyroid gland. Dual ectopia is the presence of ectopic thyroid tissue with normally located

Financial or Other, Competing Interest: None.

Submission 22-09-2016, Peer Review 04-10-2016,

Acceptance 06-10-2016, Published 13-10-2016.

Corresponding Author:

Dr. K. Neelaveni,

Associate Professor,

Department of Endocrinology,

Osmania Medical College, Hyderabad.

E-mail: neelaveni1@yahoo.co.in

DOI: 10.14260/jemds/2016/1385



thyroid as evident by imaging. Institutional Ethical Committee approval taken to analyse the data.

RESULTS

Out of total 21 patients, fifteen were female and six were male patients making the ratio of 5:2 (Fig. 1). Mean age of presentation was 13.62 years, age ranging between 3-37 years; 62% of the cases presented at less than 10 years of age as shown in Table 1. Fourteen patients (66.67%) had lingual thyroid, whereas four patients (19.02%) had thyroid gland at suprahyoid and two patients (9.52%) had at subhyoid location. Only one patient had dual thyroid (Fig. 2). Nineteen patients (90.48%) had thyroid deficiency (subclinical hypothyroidism in 38.1% and overt hypothyroidism in 52.38%) and only two (9.52%) were euthyroid (Fig. 3). Among hypothyroid patients seventeen patients (80.95%) were treated medically, only two (9.52%) patients underwent surgery. Euthyroid patients (n=2) were also treated with suppressive doses of levothyroxine. In twelve patients (57.14%) ectopic thyroid gland was detected incidentally who had lingual thyroid, whereas two patients (9.52%) with dysphagia and one patient (4.76%) with dysphagia and respiratory difficulty. Six patients (28.57%) presented with neck swelling, who had either suprahyoid or subhyoid ectopic thyroid.

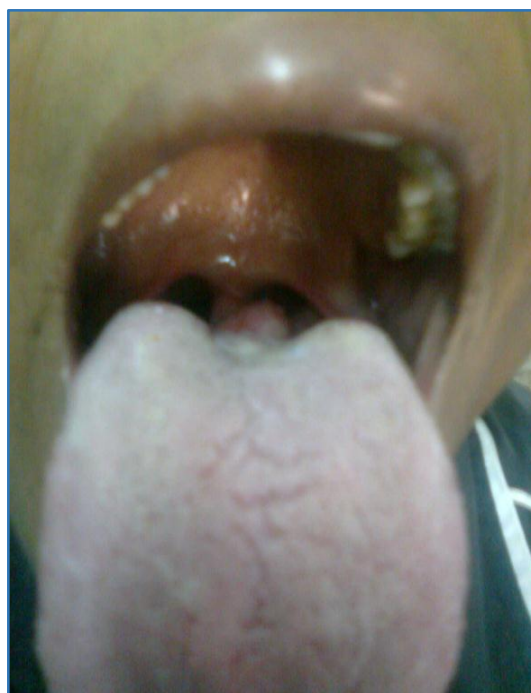
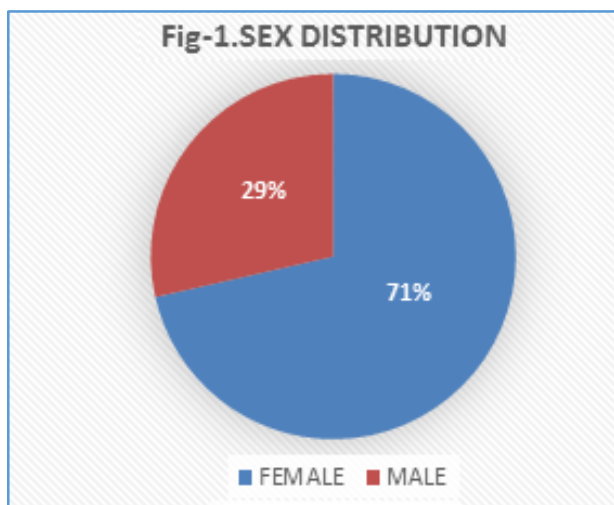
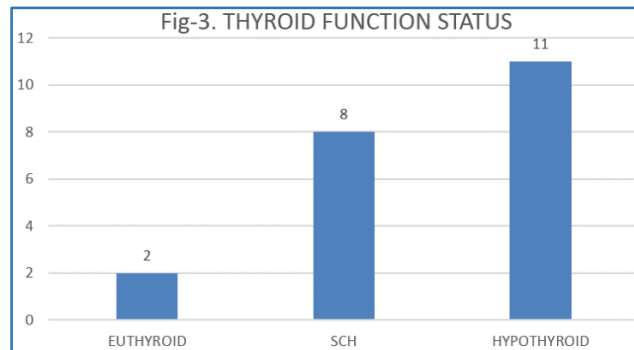


Fig. 4: Picture showing Lingual Thyroid

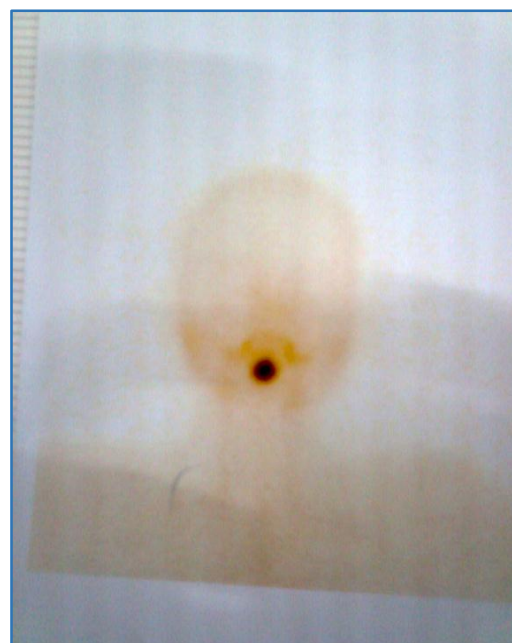
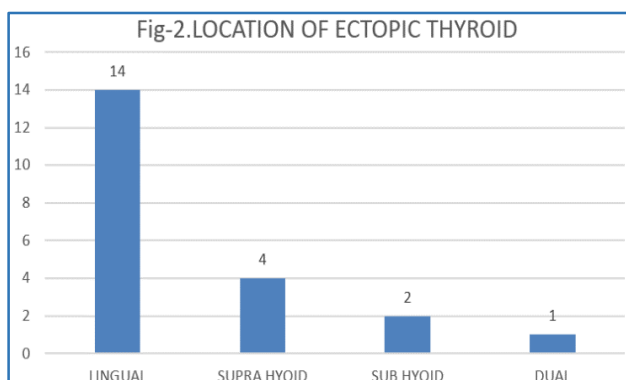


Fig. 5: Technetium 99m Pertechnetate Scan showing Lingual Thyroid

Age Group (In Years)	Frequency	Percent
0-10	13	61.9
11-20	3	14.28
21-30	4	19.04
31-40	1	4.76
Total	21	100

Table 1. Age Distribution

DISCUSSION

Ectopic thyroid is an uncommon clinical entity and its true prevalence may be underestimated due to asymptomatic nature of the condition. Thyroid gland during the process of migration remains connected to the floor of the pharyngeal gut, then it descends in front of hyoid bone to reach its pretracheal position in the 7th week of gestation. ET may be found anywhere along the line of obliterated thyroglossal duct. The exact molecular mechanisms responsible are not clearly known, but studies have demonstrated the mutations of regulatory genes encoding for transcription factors - PAX-8, TTF-1 and TTF-2, which are essential for thyroid morphogenesis and differentiation may be responsible for abnormal migration of the gland.^(7,8)

In all the case series and reviews on the ectopic thyroid reported so far, a marked female preponderance has been observed.^(5,9,10) In our series also we found female-to-male ratio of 5:2. Ectopic thyroid is commonly detected during the periods of increased demand for thyroid hormone, such as puberty and pregnancy. Because during this period ectopic gland increases in size, making it a clinically detectable mass or may cause pressure symptoms. Mean age of presentation in our series was 13.6 years, thirteen cases presented at the age below 10 years and seven cases between 11 and 30 years. Consistent with our observation, mean age of presentation in KEM Hospital study⁽⁹⁾ was 14.3 years. Age of presentation was under 30 years in case series by Somnath Saha et al⁽¹¹⁾ and Yoon et al.⁽⁵⁾

The most common location of ET is the base of the tongue in most case series. In earlier reports, this location accounted for 90% of cases.⁽¹²⁾ Okstad et al⁽¹³⁾ and Somnath Saha et al⁽¹¹⁾ found lingual thyroid, the most common followed by sublingual in their series. In contrast in KEM study,⁽⁹⁾ authors found lingual thyroid in 47% of cases, whereas sublingual in 53% of the cases. In our series, most common location was lingual followed by sublingual. Dual ectopia was found in one case in our series, who had ectopic in suprahyoid location with ectopic thyroid. Dual ectopia is very rare.⁽¹⁴⁾

Thyroid functional status was hypothyroid in 30-70% of the reported cases,⁽¹⁵⁾ only few cases were hyperthyroid.⁽¹⁶⁾ KEM study⁽⁹⁾ reported hypothyroidism in 67% of the cases and subclinical hypothyroidism in 17% of the cases. In Korean study,⁽⁵⁾ 62% of the cases had hypothyroidism and 385 were euthyroid. In another case series by Somnath Saha et al,⁽¹¹⁾ all cases were hypothyroid. In our series hypothyroidism and subclinical hypothyroidism was found in 52.38% of the cases, 38% of the cases respectively, whereas euthyroid state was found in 9.52% of the cases. None of the cases were hyperthyroid in our series.

Management of the ET should be individualised, as there is no consensus on the optimum management. Factors influencing the management decisions are the location of the ET, size, functional status and compressive or obstructive symptoms. Levothyroxine therapy is recommended for

patients with either subclinical hypothyroidism or frank hypothyroidism. Treatment with levothyroxine reduces the size of the gland. Some authors recommend levothyroxine therapy for euthyroid patients also.⁽¹⁷⁾ Careful observation and follow-up may be a better approach for patients with asymptomatic ectopic thyroid, which are detected incidentally and functionally euthyroid. Surgery is indicated for patients with large ectopic causing upper airway obstruction, haemorrhage, infection or malignant degeneration. Post-operatively these patients require levothyroxine, because ectopic thyroid is the only functioning tissue. Autotransplantation of excised thyroid has been attempted.^(18,19) Steinwald et al⁽²⁰⁾ reported 30% of patients remained euthyroid with autotransplantation, not requiring levothyroxine therapy. Radioactive ablation may be another approach for elderly patients with symptomatic ectopic, who refuse or not fit for surgery.⁽¹⁹⁾ In our series 81% of the cases who were hypothyroid treated medically with levothyroxine, 9.52% of the euthyroid patients also received medical therapy, whereas 9.52% underwent surgery who had large ectopic with obstruction. In KEM series, 86% of the cases were treated medically and surgery was performed in 14% of the cases.

CONCLUSION

Ectopic thyroid gland is rare, but should be considered in the evaluation of midline neck swelling, especially in children with hypothyroidism. Clinical examination, thyroid profile and nuclear imaging aid in the diagnosis. Management should be individualised.

REFERENCES

1. Comajuan SM, Ayerbe JL, Ferrer BR, et al. An intracardiac ectopic thyroid mass. *Eur J Echocardiogr* 2009;10(5): 704-6.
2. Spinner RJ, Moor KL, Gottfried MR. Thoracic intrathyroidic thyroid. *Ann Surg* 1994;220(1):91-6.
3. Eyuboglu E, Kapan M, Ipek T, et al. Ectopic thyroid in the abdomen: report of a case. *Surg Today* 1999;29(5):472-4.
4. Hagiuda J, Kuroda I, Tsukamoto T. Ectopic thyroid in an adrenal mass: a case report. *BMC Urol* 2006;6:18.
5. Yoon JS, Won KC, Cho IH, et al. Clinical characteristics of ectopic thyroid in Korea. *Thyroid* 2007;17(11):1117-21.
6. Sauk JJ. Ectopic lingual thyroid. *J Pathol* 1970;102(4): 239-45.
7. Gillam MP, Kopp P. Genetic regulation of thyroid development. *Curr Opin Pediatr* 2001;13(4):358-63.
8. Felice DM, Lauro DR. Thyroid development and its disorders: genetic and molecular mechanisms. *Endocrine Reviews* 2004;25(5):722-46.
9. Gopal RA, Acharya SV, Bandgar T, et al. Clinical profile of ectopic thyroid in Asian Indians: a single-center experience. *Endocrine Practice* 2009;15(4):322-5.
10. Kaplan M, Kauli R, Lubin E, et al. Ectopic thyroid gland. A clinical study of 30 children & review. *J Pediatr* 1978;92(2):205-9.
11. Saha S, Ghosh A, Pal S, et al. Ectopic thyroid tissue –a case series. *Philippine Journal of Otolaryngology-Head And Neck Surgery* 2013;28(1):10-4.
12. Noyek AM, Friedberg J. Thyroglossal duct and ectopic thyroid disorders. *Otolaryngol Clin North Am* 1981;14(1):187-201.

13. Okstad S, Mair IW, Sundsfjord JA, et al. Ectopic thyroid tissue in the head and neck. *J Otolaryngol* 1986;15(1): 52-5.
14. Huang TS, Chen HY. Dual thyroid ectopia with a normally located pretracheal thyroid gland: case report and literature review. *Head Neck* 2007;29(9):885-8.
15. Danner C, Bodenner D, Breau R. Lingual thyroid: iodine 131: a viable treatment modality revisited. *Am J Otolaryngol* 2001;22(4):276-81.
16. Shah BC, Ravichand CS, Juluri S, et al. Ectopic thyroid cancer. *Ann Thorac Cardiovasc Surg* 2007;13(2):122-4.
17. Kansal P, Sakati N, Rifai A, et al. Lingual thyroid. Diagnosis and treatment. *Arch Intern Med* 1987;147(11):2046-48.
18. Hazarika P, Siddiqui SA, Pujary K, et al. Dual ectopic thyroid: a report of two cases. *J Laryngol Otol* 1998;112(4):393-5.
19. Kalan A, Tariq M. Lingual thyroid gland: clinical evaluation and comprehensive management. *Ear Nose Throat J* 1999;78(5):340-9.
20. Steinwald OP, Muehrcke RC, Economou SG. Surgical correction of complete lingual ectopia of the thyroid gland. *Surg Clin North Am* 1970;50(5):1177-86.